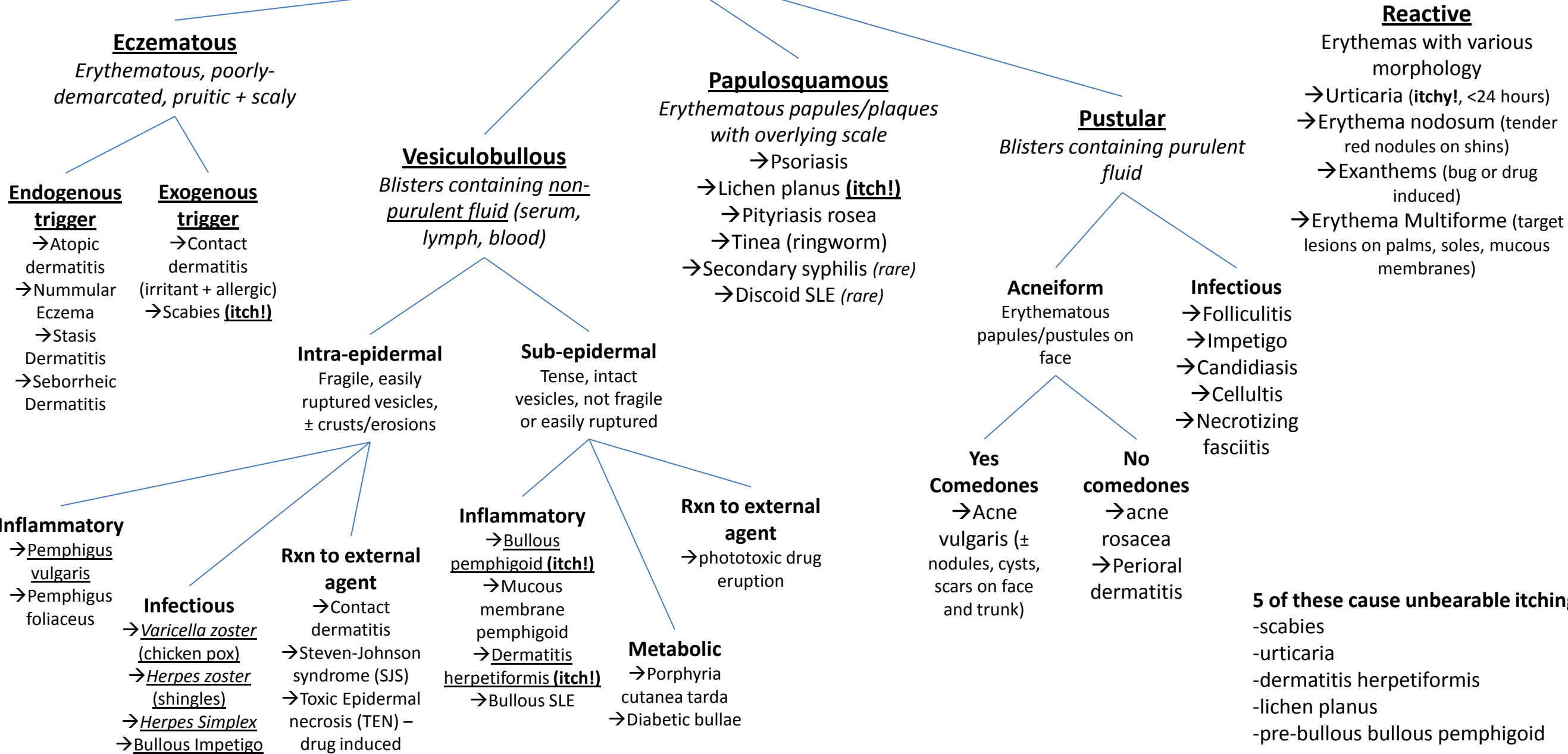


Skin Rashes



Eczematous
Erythematous, poorly-demarcated, pruritic + scaly

Endogenous trigger
 → Atopic dermatitis
 → Nummular Eczema
 → Stasis Dermatitis
 → Seborrheic Dermatitis

Exogenous trigger
 → Contact dermatitis (irritant + allergic)
 → Scabies **(itch!)**

Vesiculobullous
Blisters containing non-purulent fluid (serum, lymph, blood)

Intra-epidermal
 Fragile, easily ruptured vesicles, ± crusts/erosions

Sub-epidermal
 Tense, intact vesicles, not fragile or easily ruptured

Inflammatory
 → Pemphigus vulgaris
 → Pemphigus foliaceus

Infectious
 → Varicella zoster (chicken pox)
 → Herpes zoster (shingles)
 → Herpes Simplex
 → Bullous Impetigo

Rxn to external agent
 → Contact dermatitis
 → Steven-Johnson syndrome (SJS)
 → Toxic Epidermal necrosis (TEN) – drug induced

Inflammatory
 → Bullous pemphigoid **(itch!)**
 → Mucous membrane pemphigoid
 → Dermatitis herpetiformis **(itch!)**
 → Bullous SLE

Rxn to external agent
 → phototoxic drug eruption

Metabolic
 → Porphyria cutanea tarda
 → Diabetic bullae

Papulosquamous
Erythematous papules/plaques with overlying scale
 → Psoriasis
 → Lichen planus **(itch!)**
 → Pityriasis rosea
 → Tinea (ringworm)
 → Secondary syphilis *(rare)*
 → Discoid SLE *(rare)*

Pustular
Blisters containing purulent fluid

Acneiform
 Erythematous papules/pustules on face

Yes Comedones
 → Acne vulgaris (± nodules, cysts, scars on face and trunk)

No comedones
 → acne rosacea
 → Perioral dermatitis

Infectious
 → Folliculitis
 → Impetigo
 → Candidiasis
 → Cellulitis
 → Necrotizing fasciitis

Reactive
 Erythemas with various morphology
 → Urticaria **(itchy!, <24 hours)**
 → Erythema nodosum (tender red nodules on shins)
 → Exanthems (bug or drug induced)
 → Erythema Multiforme (target lesions on palms, soles, mucous membranes)

5 of these cause unbearable itching:
 -scabies
 -urticaria
 -dermatitis herpetiformis
 -lichen planus
 -pre-bullous bullous pemphigoid