Pelvic masses

Other
→**Pelvic kidney** (can look like odd mass in ultrasound b/c its too far down)
→**Peritoneal cysts** (arising from peritoneum)

GI
Bowel distension (see GI scheme)

Gynecology

Uterine masses

Benign
→**Pregnancy** (most common benign uterine mass)
→**Fibroids** (second most common mass)

Malignant
→Uterine cancers

Ectopic ovarian pregnancy (rare)

Hyperplastic cysts

Endometrioma
Nodules usually on ovaries (80%), but can be on cul-de-sacs and pelvic ligaments

Polycystic Ovarian Syndrome (PCOS)

Inflammatory
→Tubo-ovarian abscess (TOA)

Neoplastic
→Epithelial tumors
→Germ cell tumors
→Stromal cell tumors

Benign
→Cystademona (epithelial cell cyst)
→Dermoid cyst (germ cell tumor)

Malignant
"Ovarian cancer"
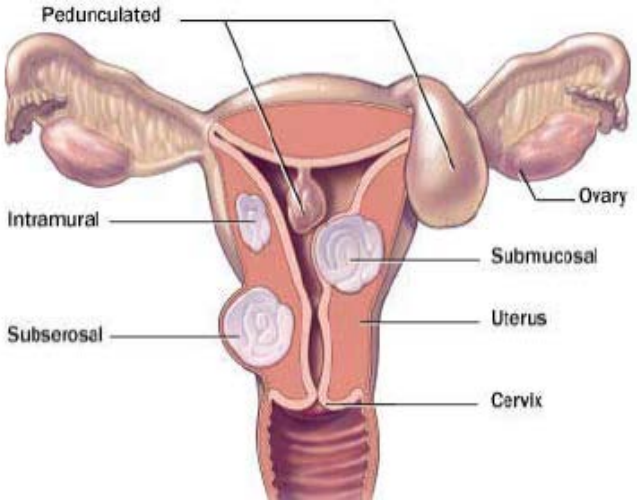
Functional cysts
(small, physiologic)
→Follicular cyst
→Corpus luteal cyst
→Thecal lutein cyst